

# Extreme Cases of Pilonidal Disease requiring Plastic Surgery

**LOUIS BANKA JOHNSON, M.D., Ph.D.  
PELVIC FLOOR CENTRE  
MALMO UNIVERSITY HOSPITAL – SWEDEN**



---

**ACKNOWLEDGEMENTS TO MY PLASTIC SURGERY COLLEAGUES:**

**BJORN SCHÖNMEYR, ASSOC. PROF.**

**MARTIN ÖBERG, M.D., Ph.D.**

**PROF. HENRY SVENSSON**

**PLASTIC SURGERY DEPARTMENT**

**MALMÖ UNIVERSITY HOSPITAL**



While Minimally Invasive Surgery can be a sound option for most cases of Pilonidal Disease (PD), some rare patients may require more extensive surgery.

In addition, PD can be complicated by other conditions such as hidradenitis suppurativa and/ or fistula in ano.

In these instances, treatment can be achieved by using a temporary diverting loop colostomy followed by plastic surgery.

In cases of anal fistula, this condition must be treated first.

---

Some advanced / extreme cases of PD are here presented.

# Tips to enhance wound treatment

√ Hair removal /depilation / epilation by LASER treatment before and after surgery has healed

√ Preop local treatment with Prontosan® (polyhexamide-betain solution; anti biofilm)

√ Temporary diverting colostomy & Radical surgical resection

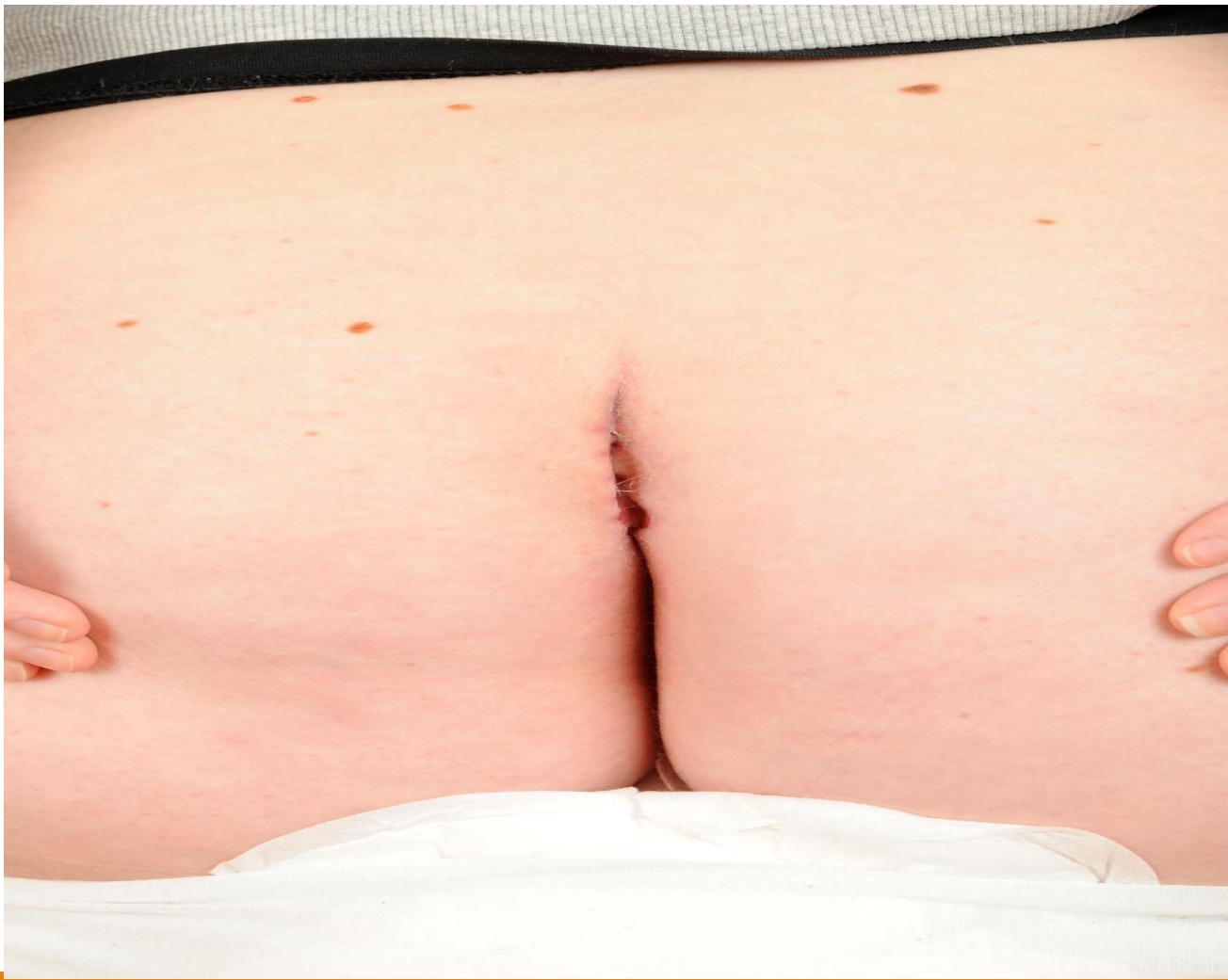NOTE: "*Deep Cleavage Sign*" (by Johnson-Öberg & Svensson)

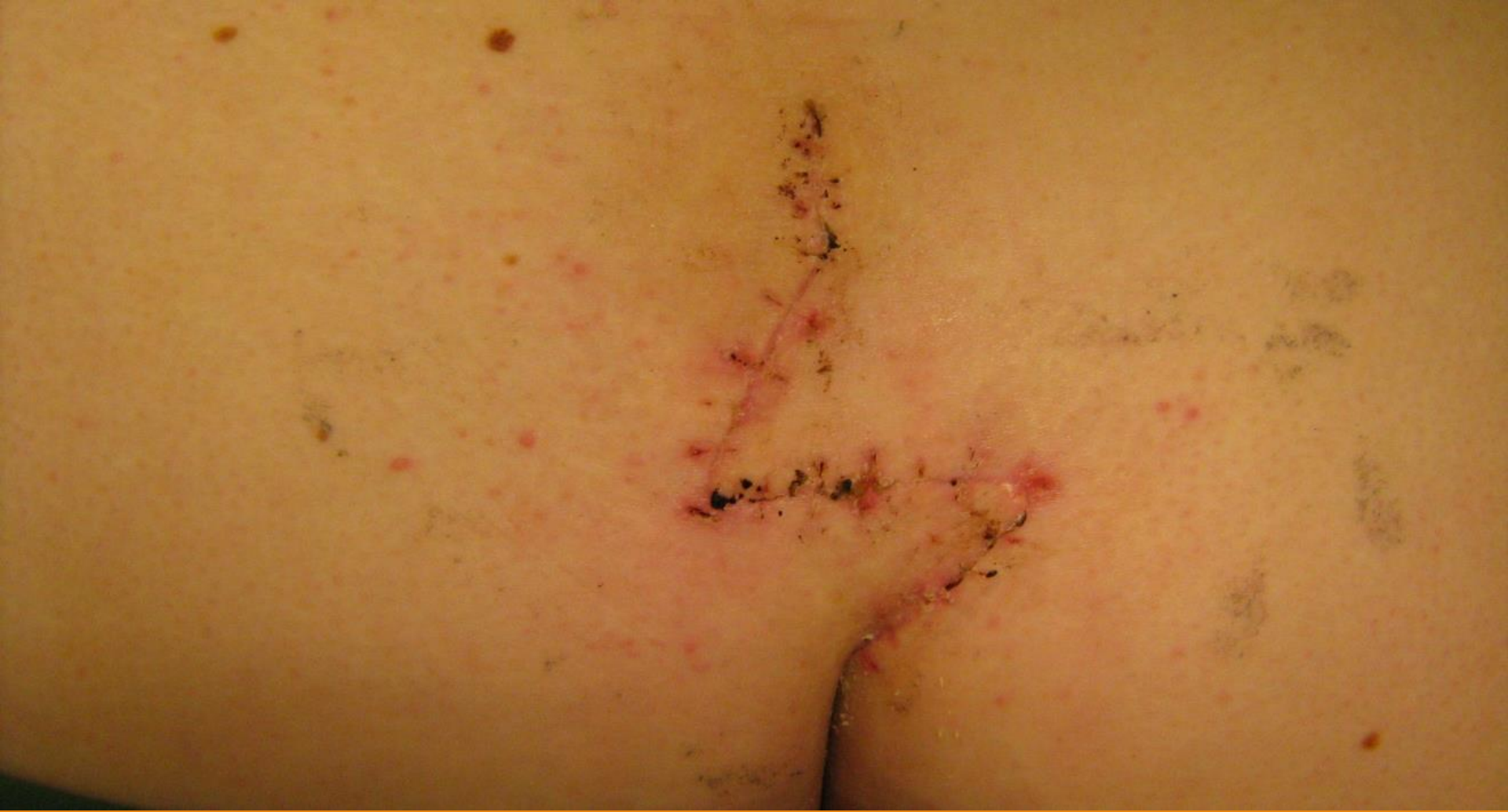Beware of patients with deep cleavage between the buttocks!  
Usually, this is a sign of potentially difficult wound healing and treatment

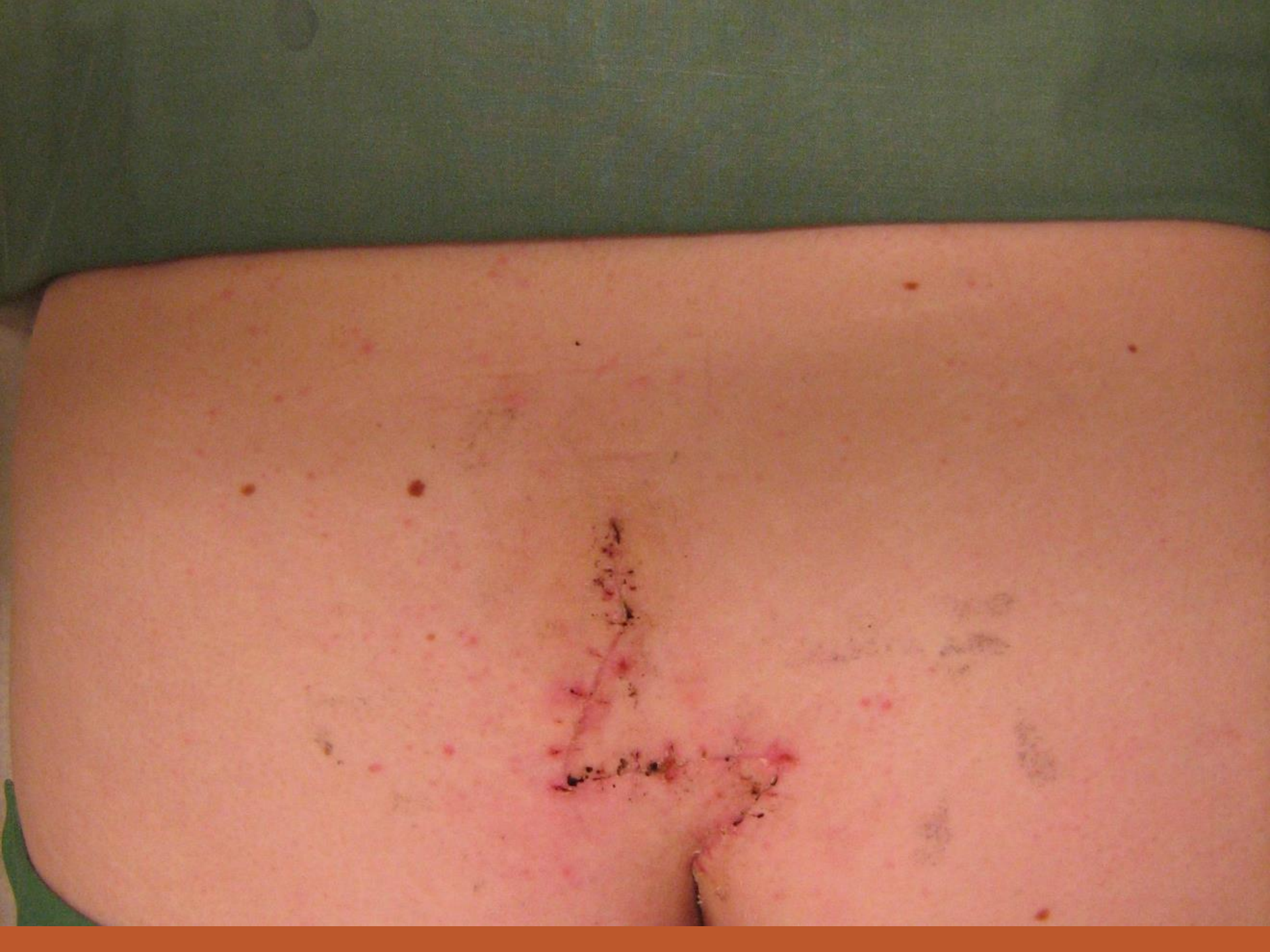# Z-PLASTY

18 yr old lady. Received PD surgery >10 times. Everything had failed, from local excision (both laid open and closed) to Vacuum assisted treatments (VAC). Finally cured by Z-plasty

---





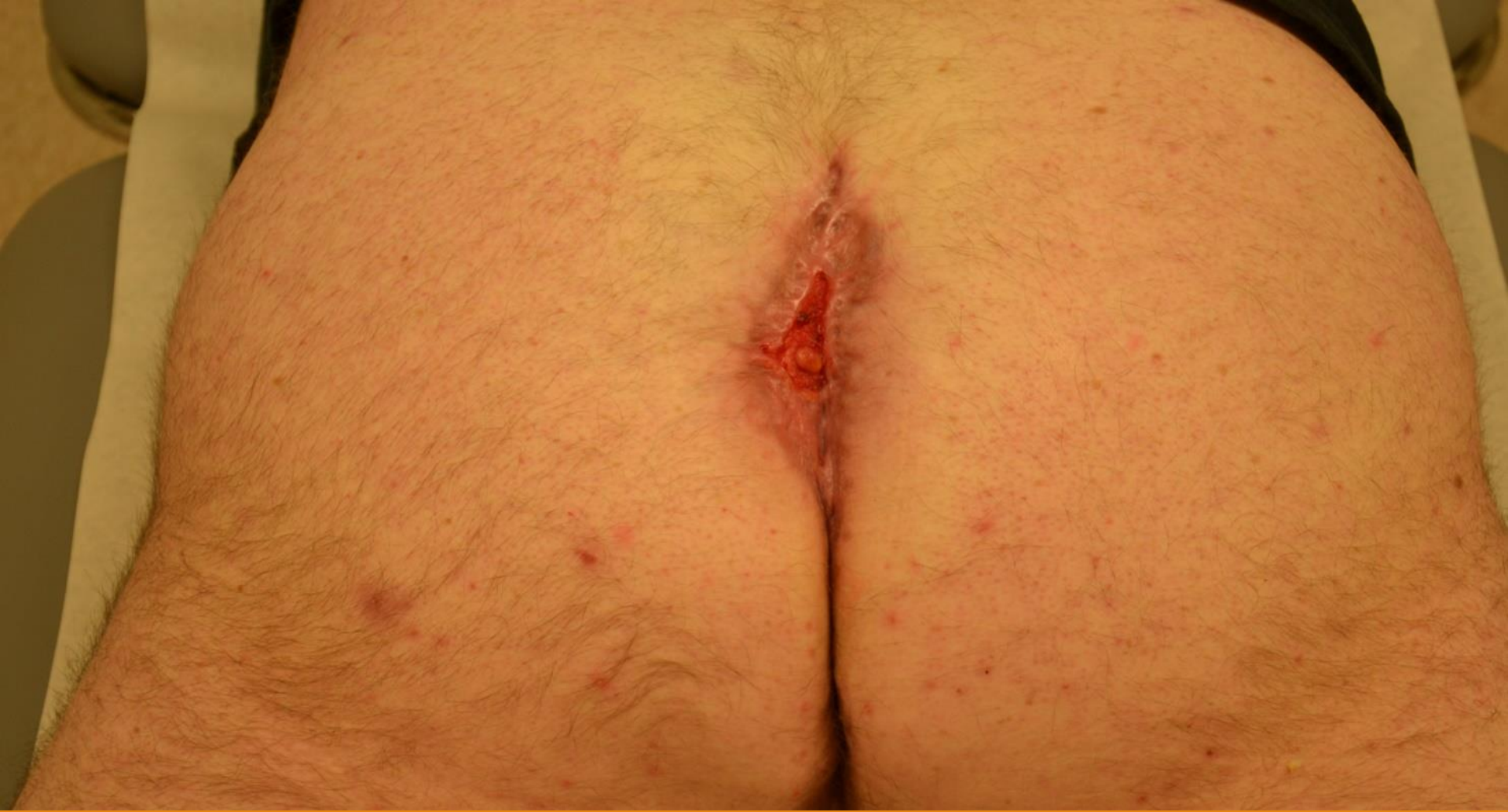

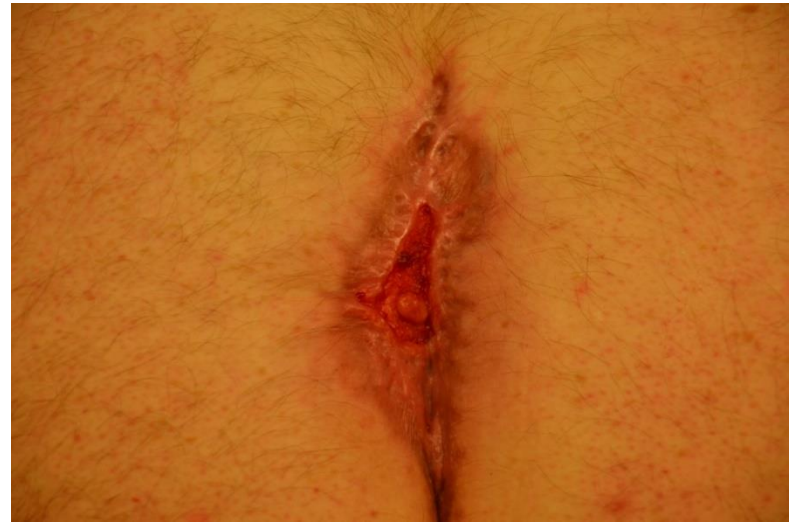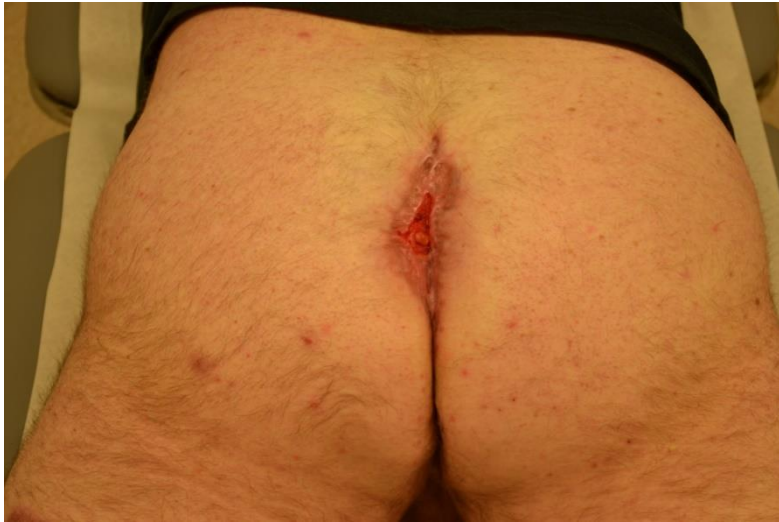# MESH

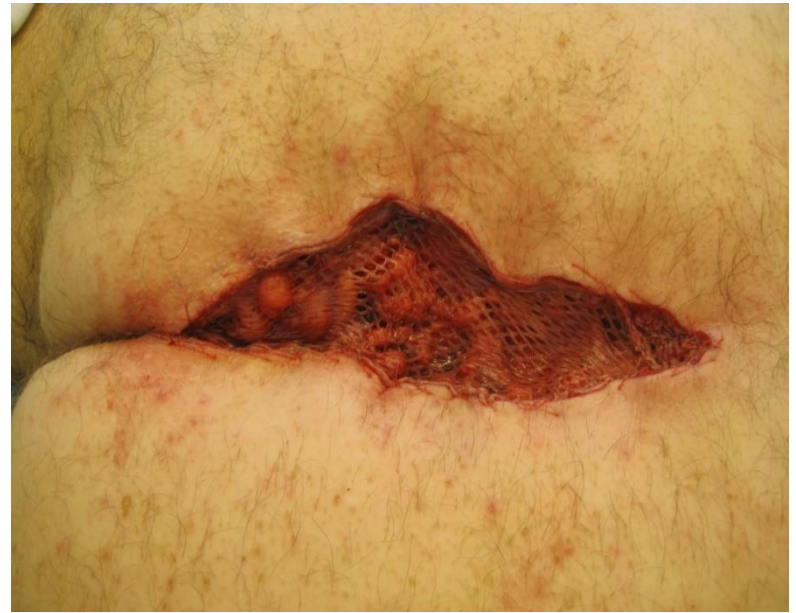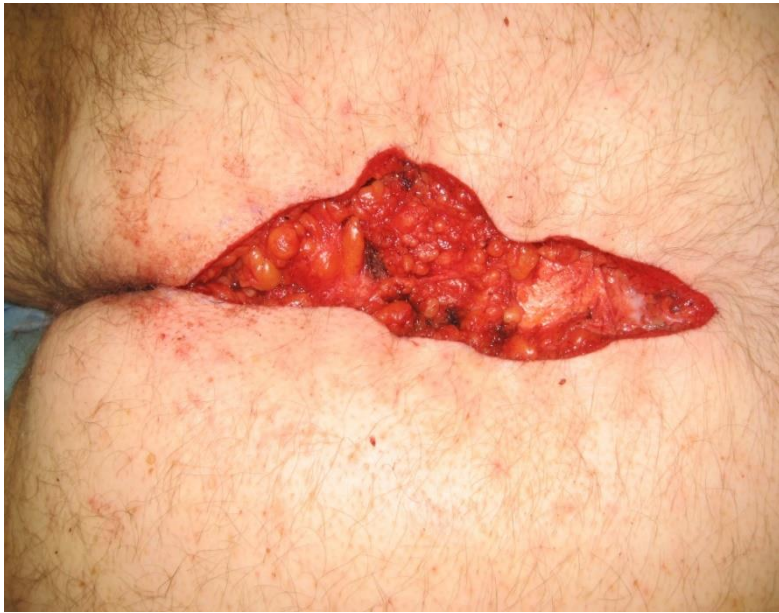## Case 1

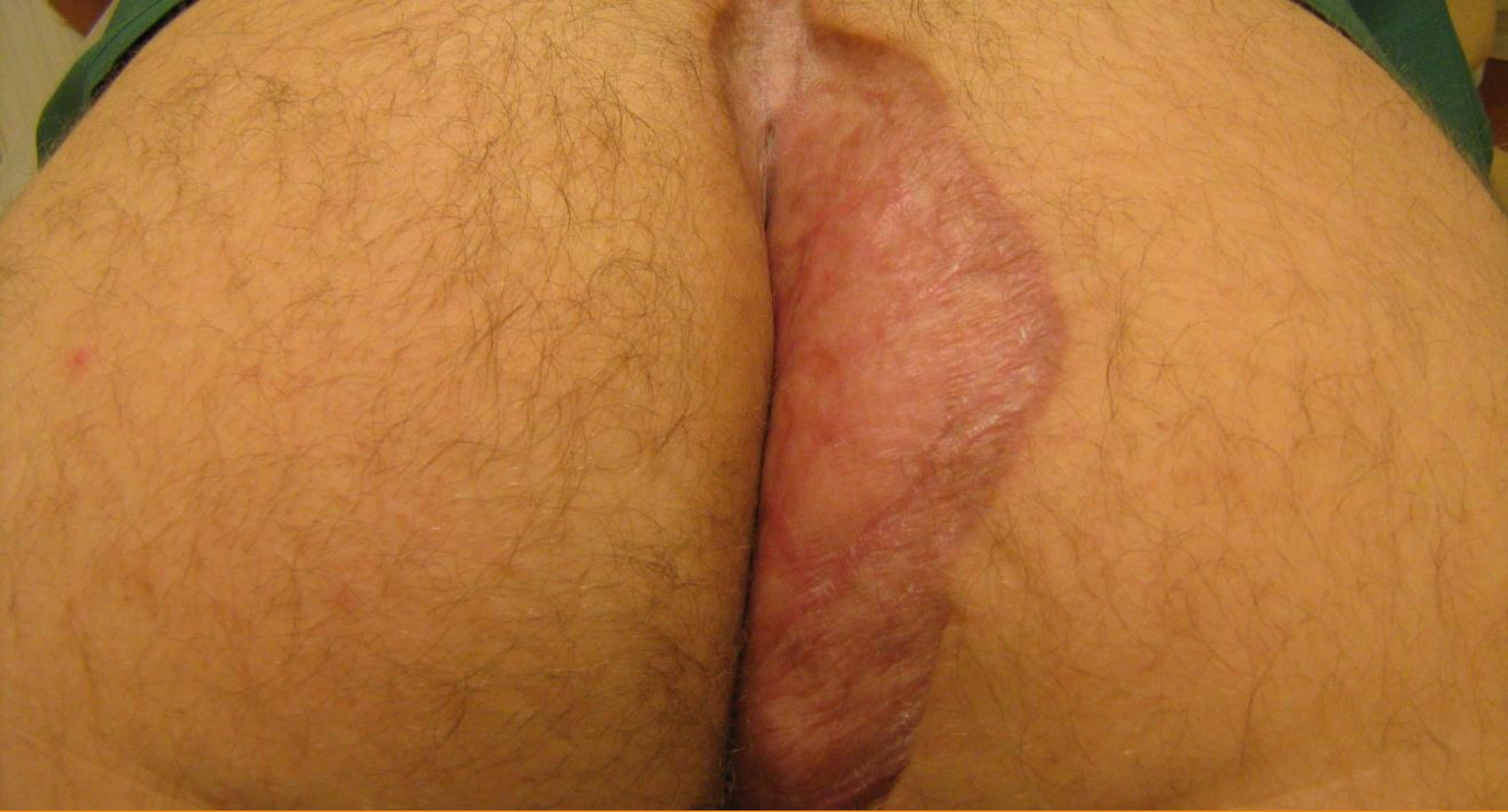Recurrent PD after multiple procedures finally treated by autologous split-thickness/mesh graft











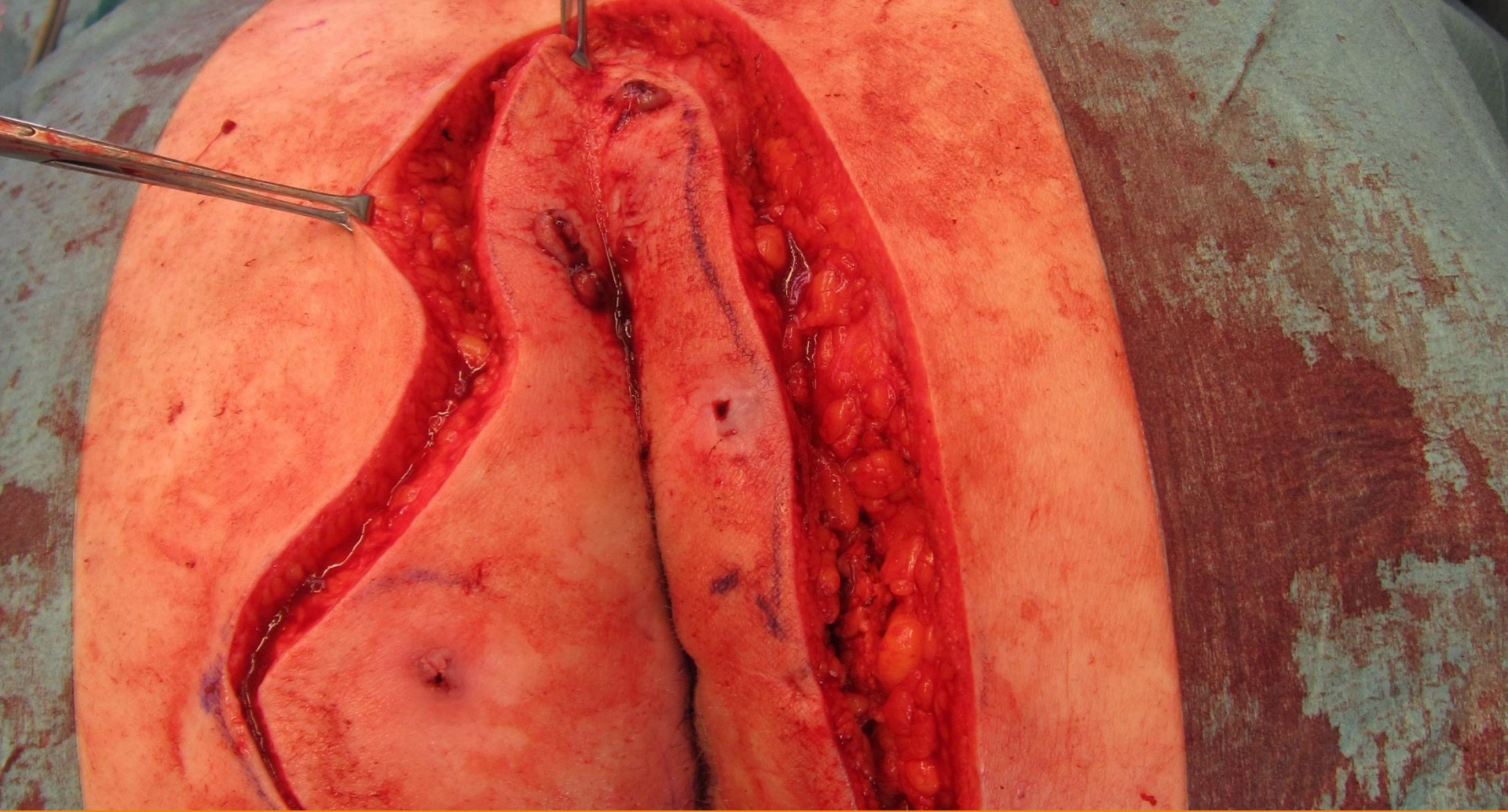
6 months follow up.

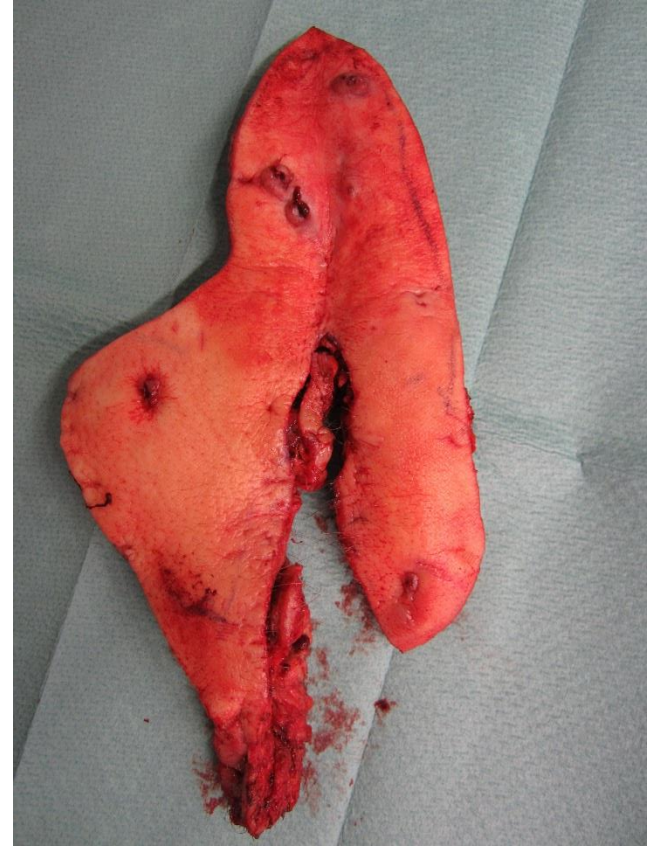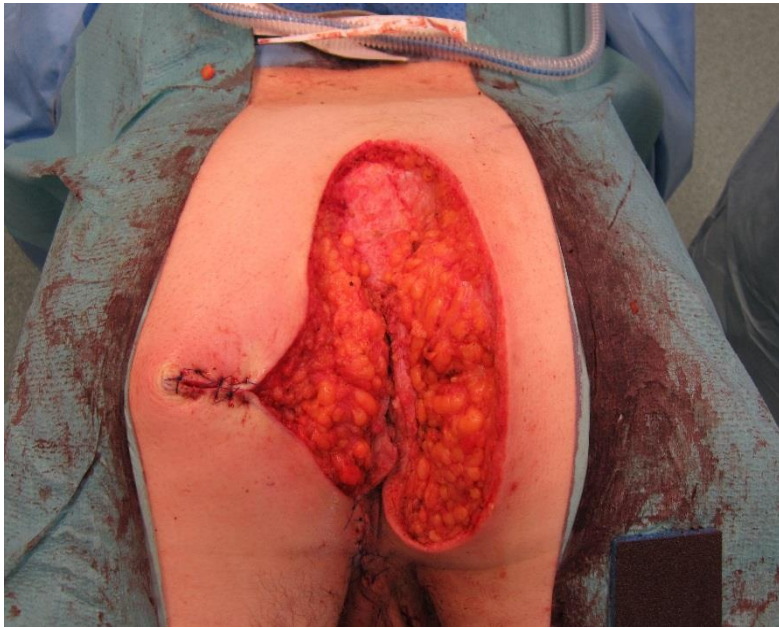By 1 year usually ridges and uneven areas start to soften and even up.

# MESH

## Case 2

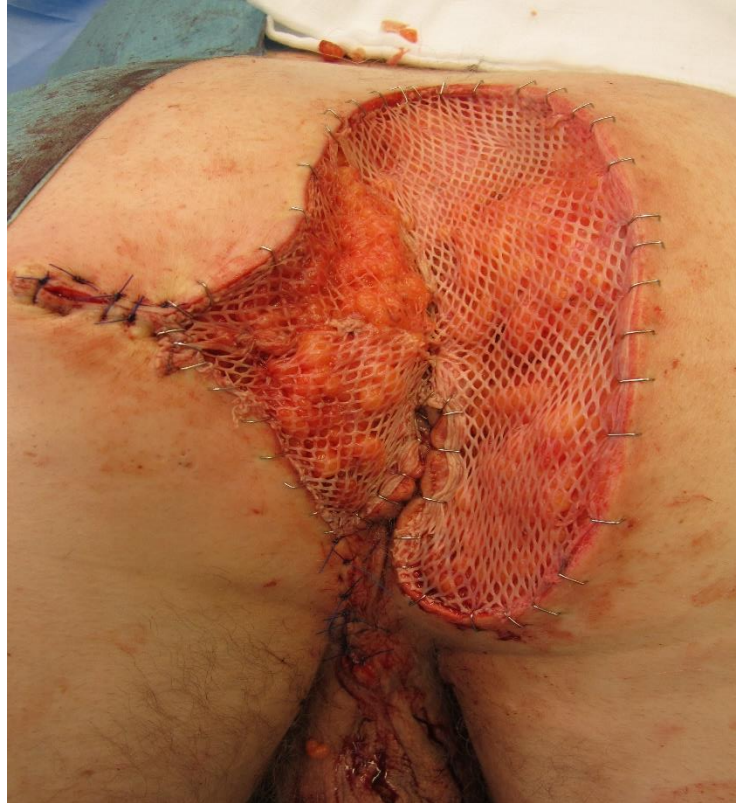Recurrent PD complicated by perianal disease –  
Hidradenitis suppurativa & Fistula in ano





# Autologous split-thickness / mesh graft

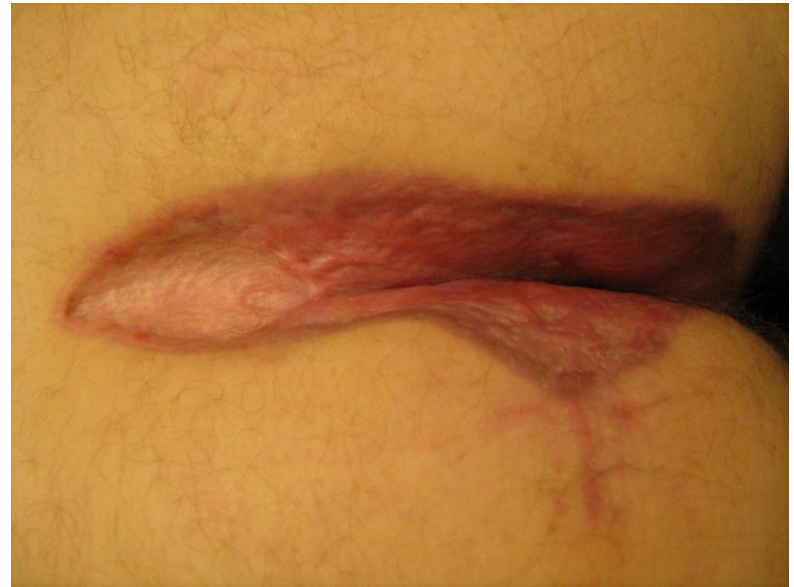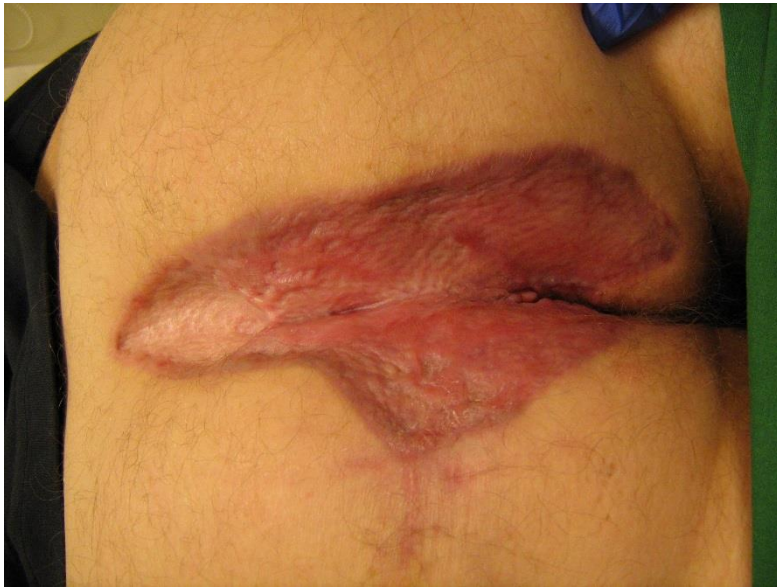---





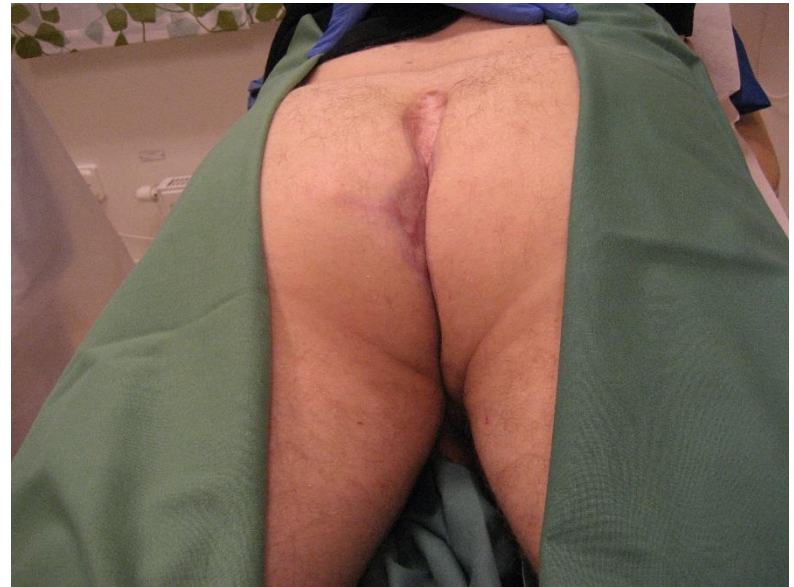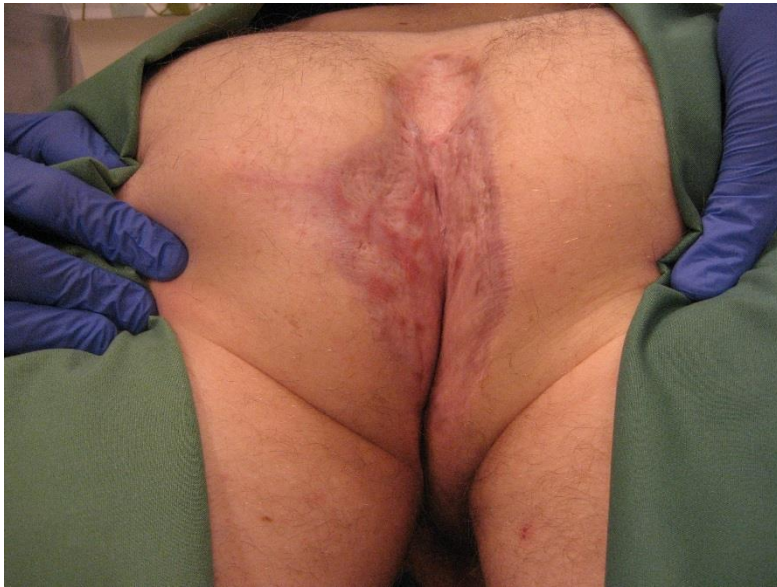## 3.5 months after surgery

---



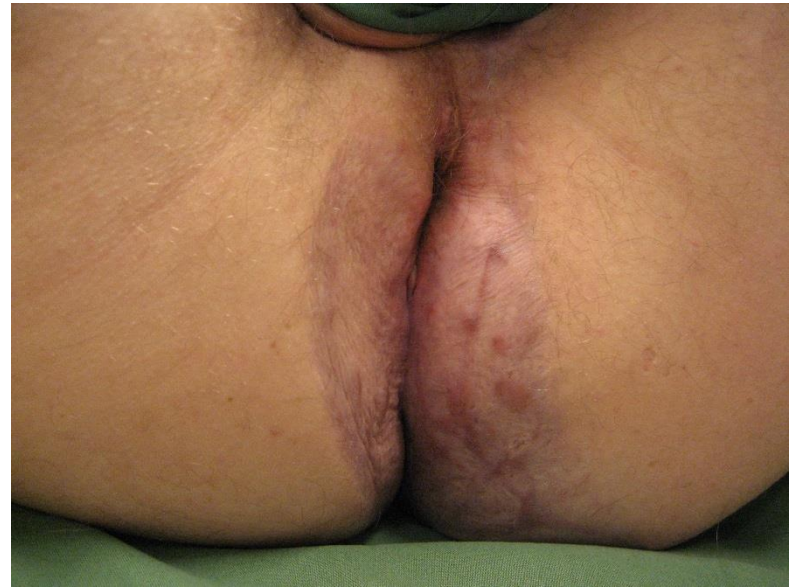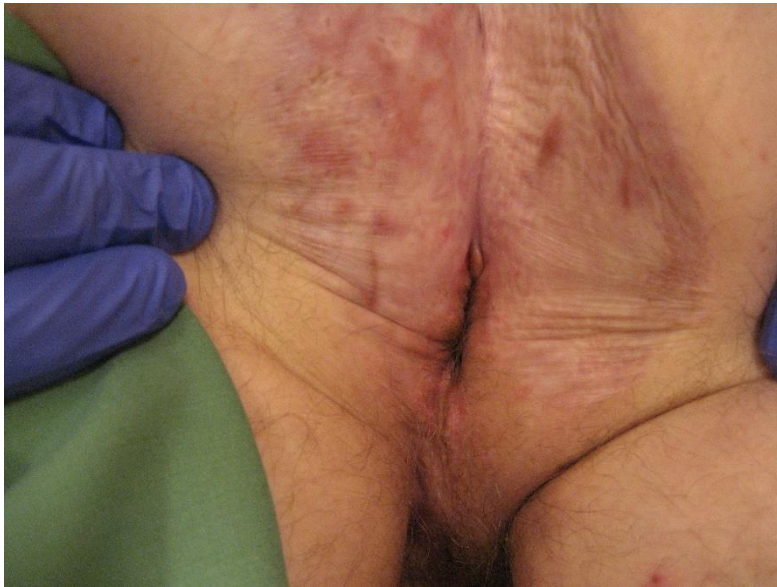# 9 months after surgery

---



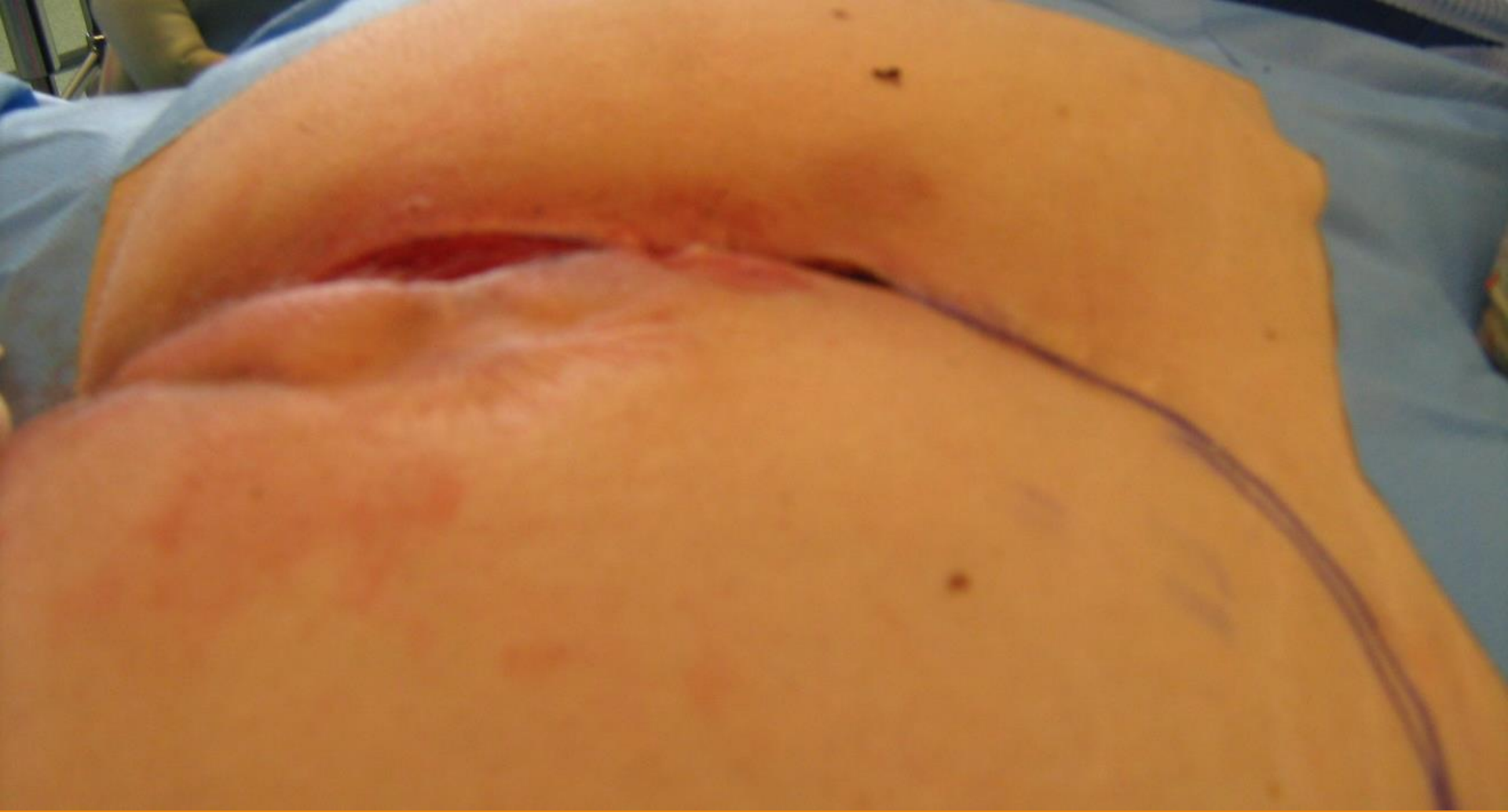# 9 months after surgery

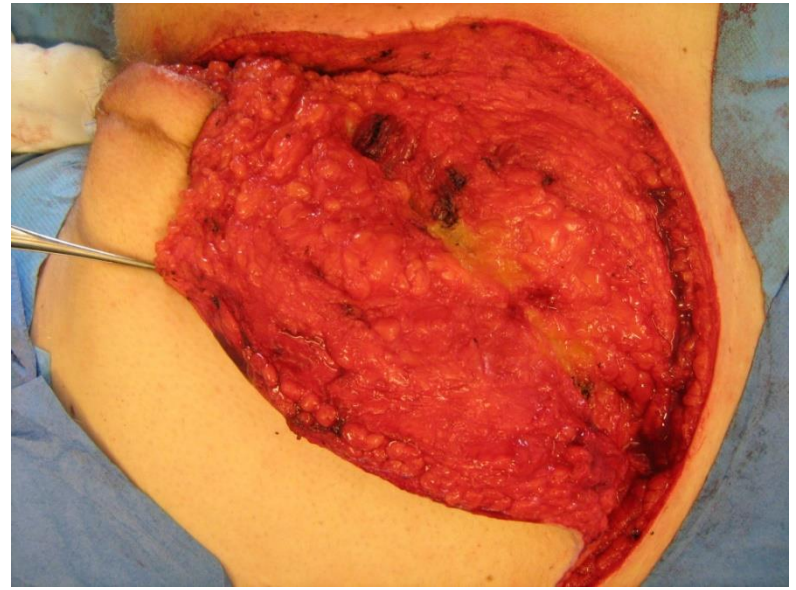
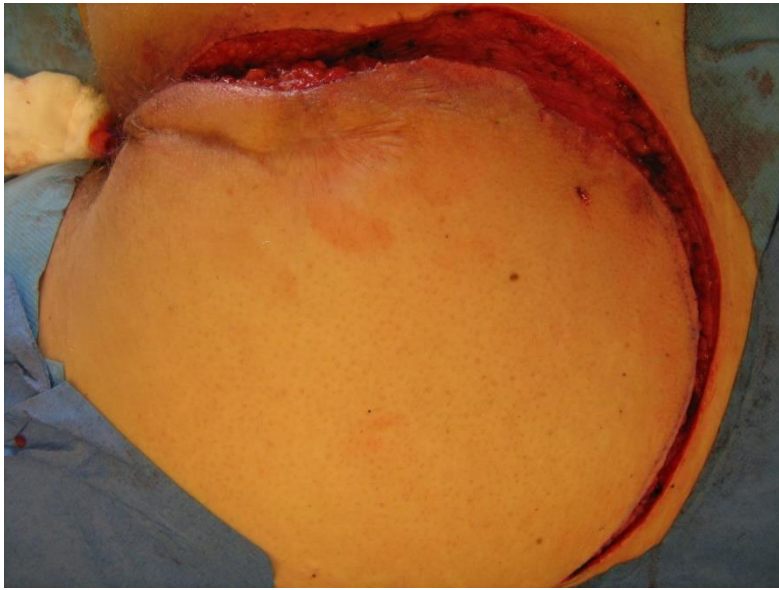---

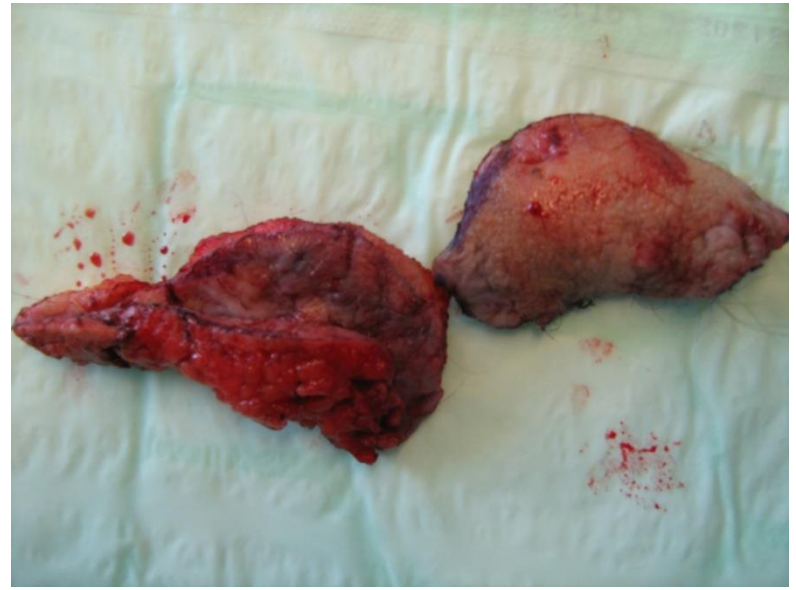
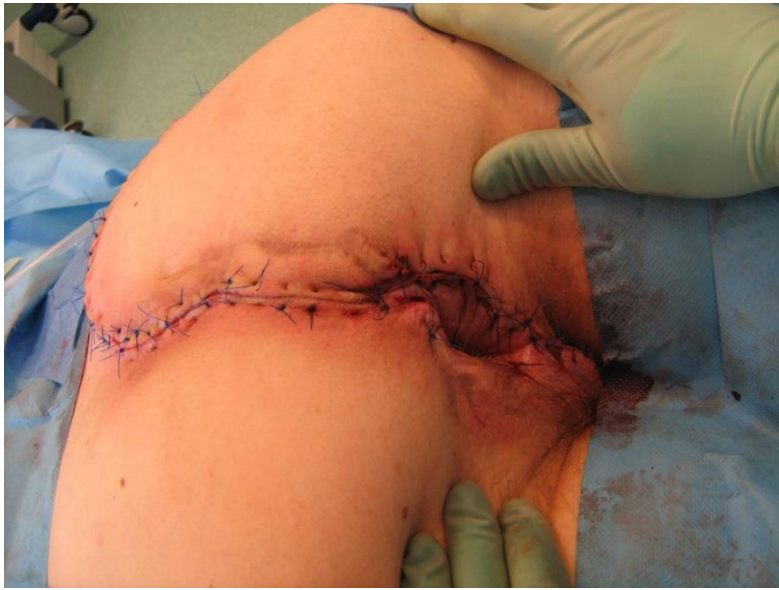

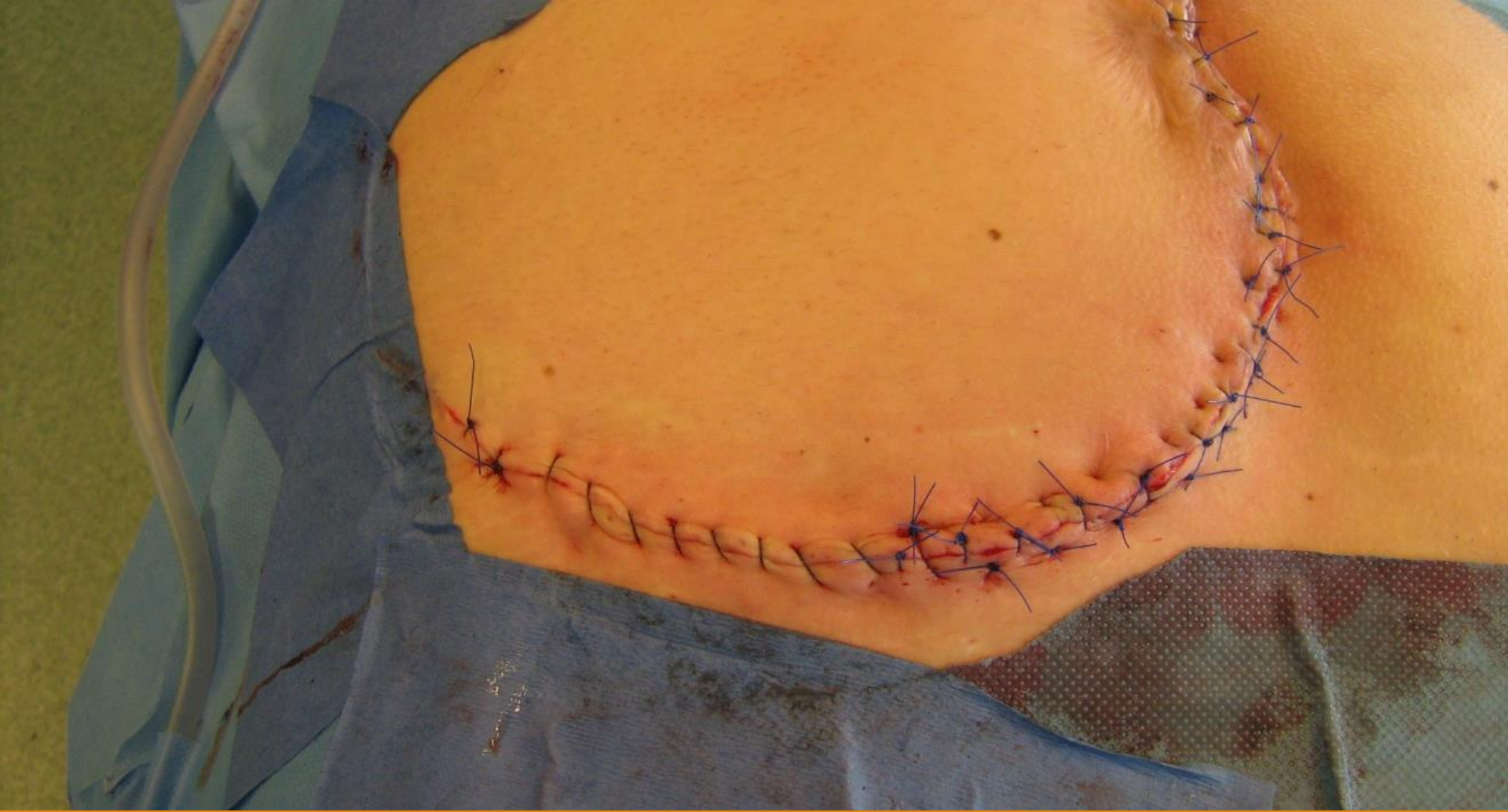# FLAP

Recurrent PD combined with perianal disease treated with a local rotational flap (caudal base/pedicle)









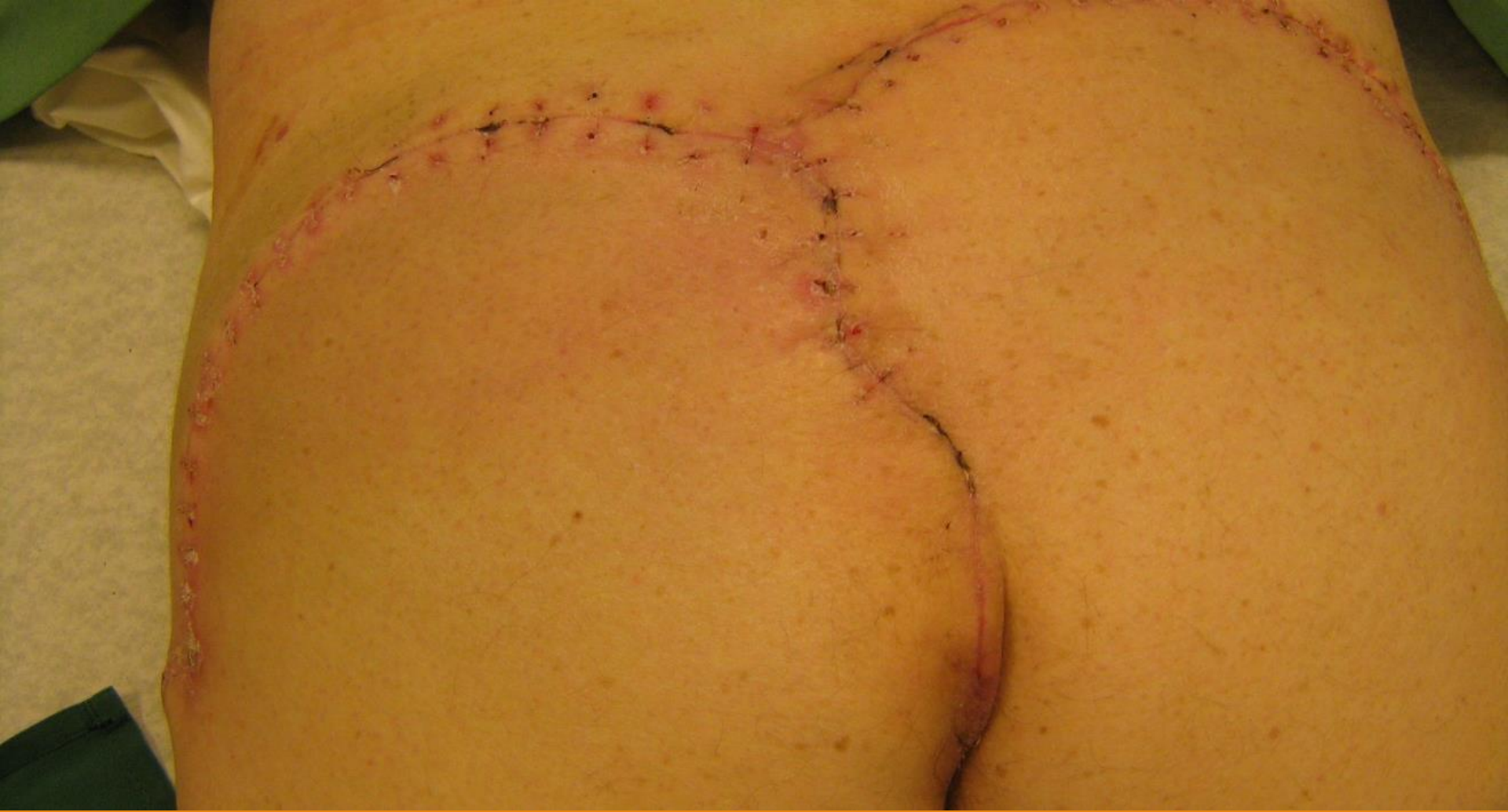View from lower back



# DOUBLE FLAP

## Case 1

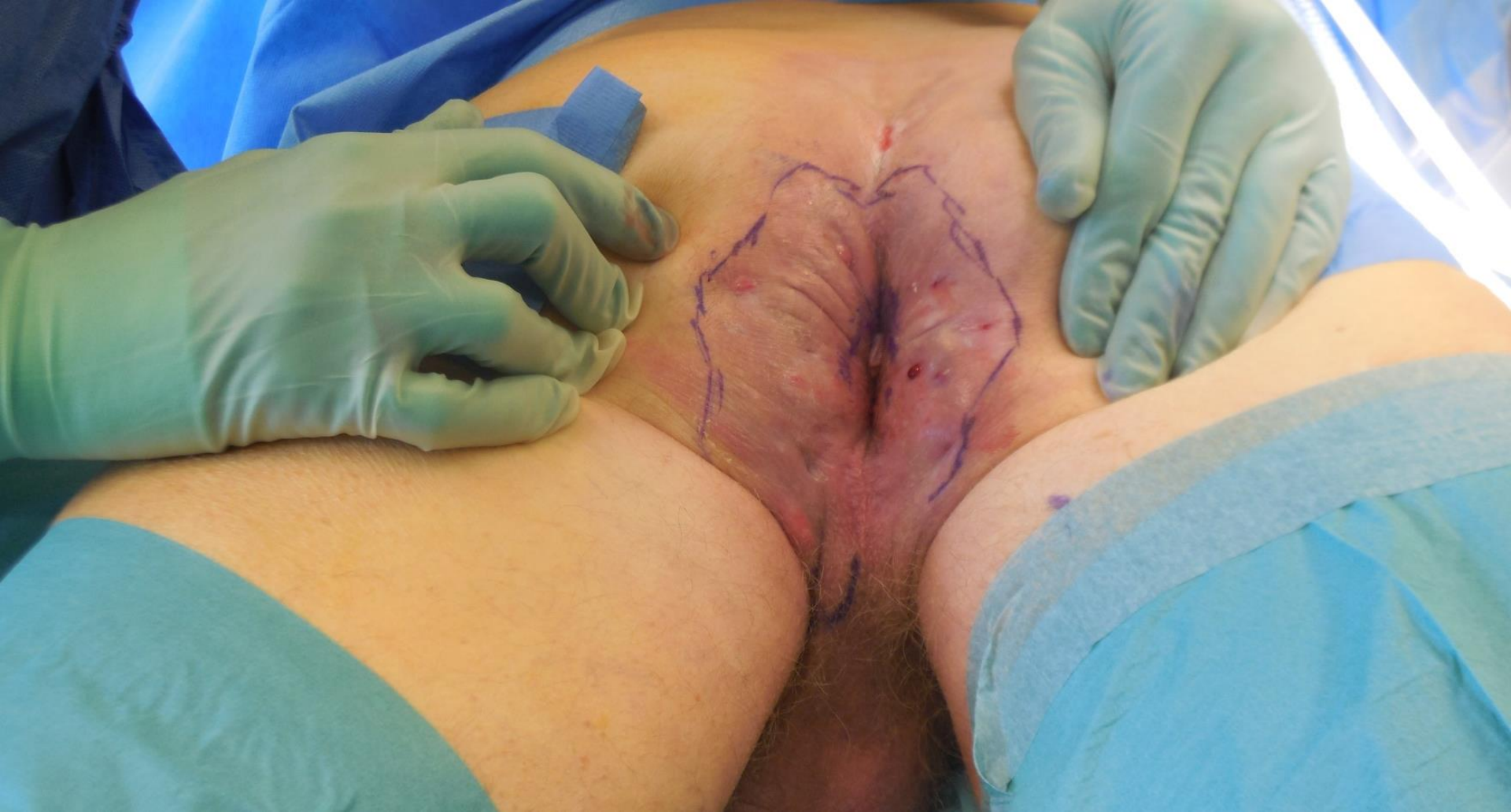Recurrent PD combined with perianal disease treated with double rotational flaps (caudal base)



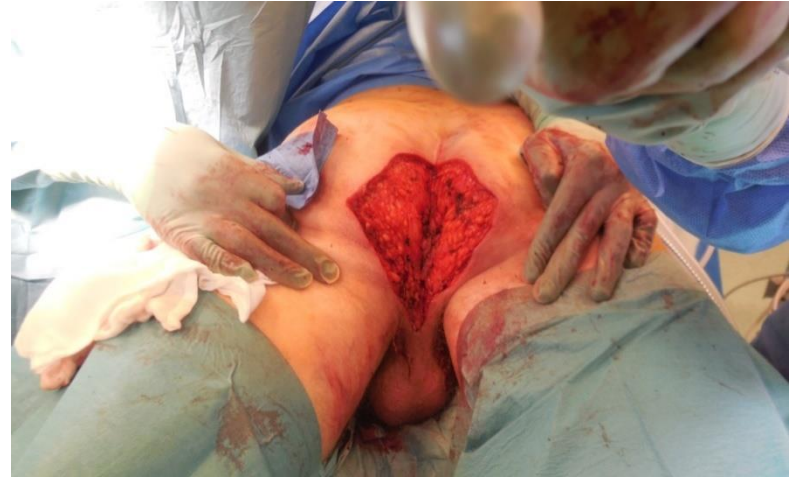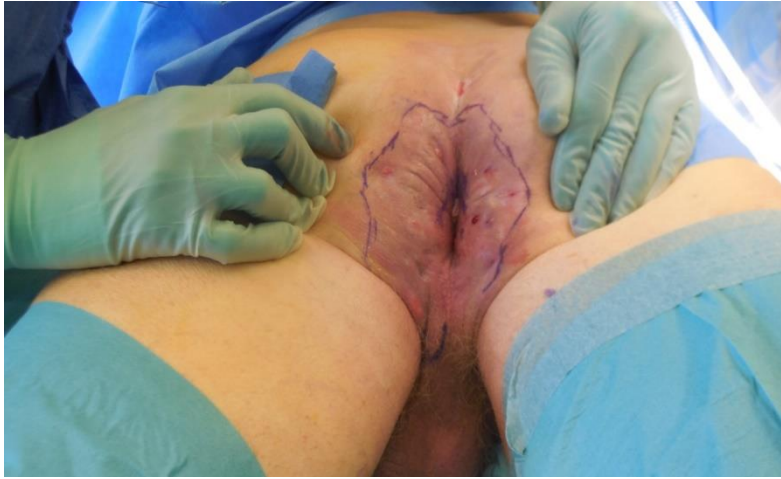# DOUBLE FLAP

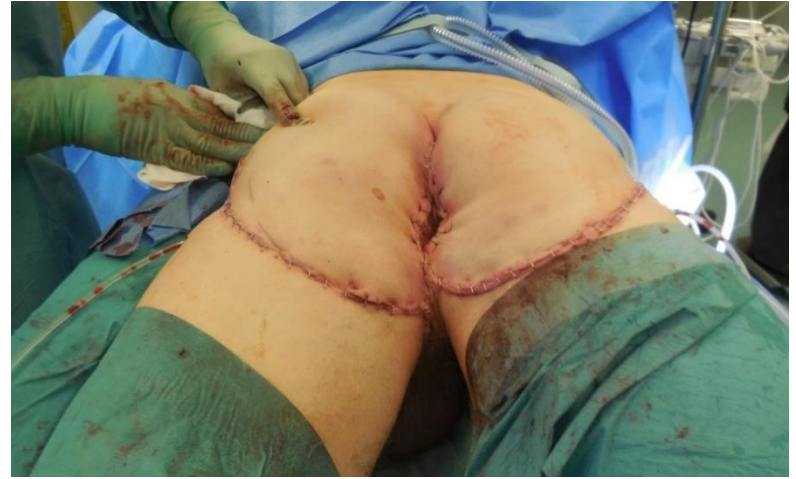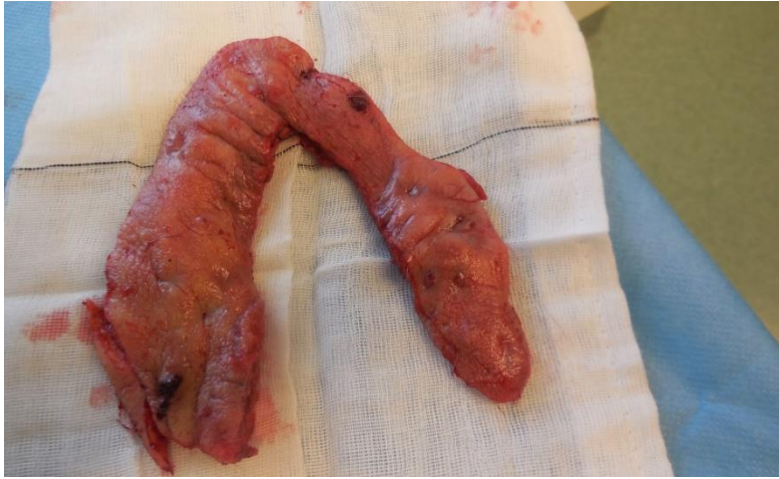## Case 2

Recurrent PD combined with perianal disease treated with double rotational flaps (caudal base)



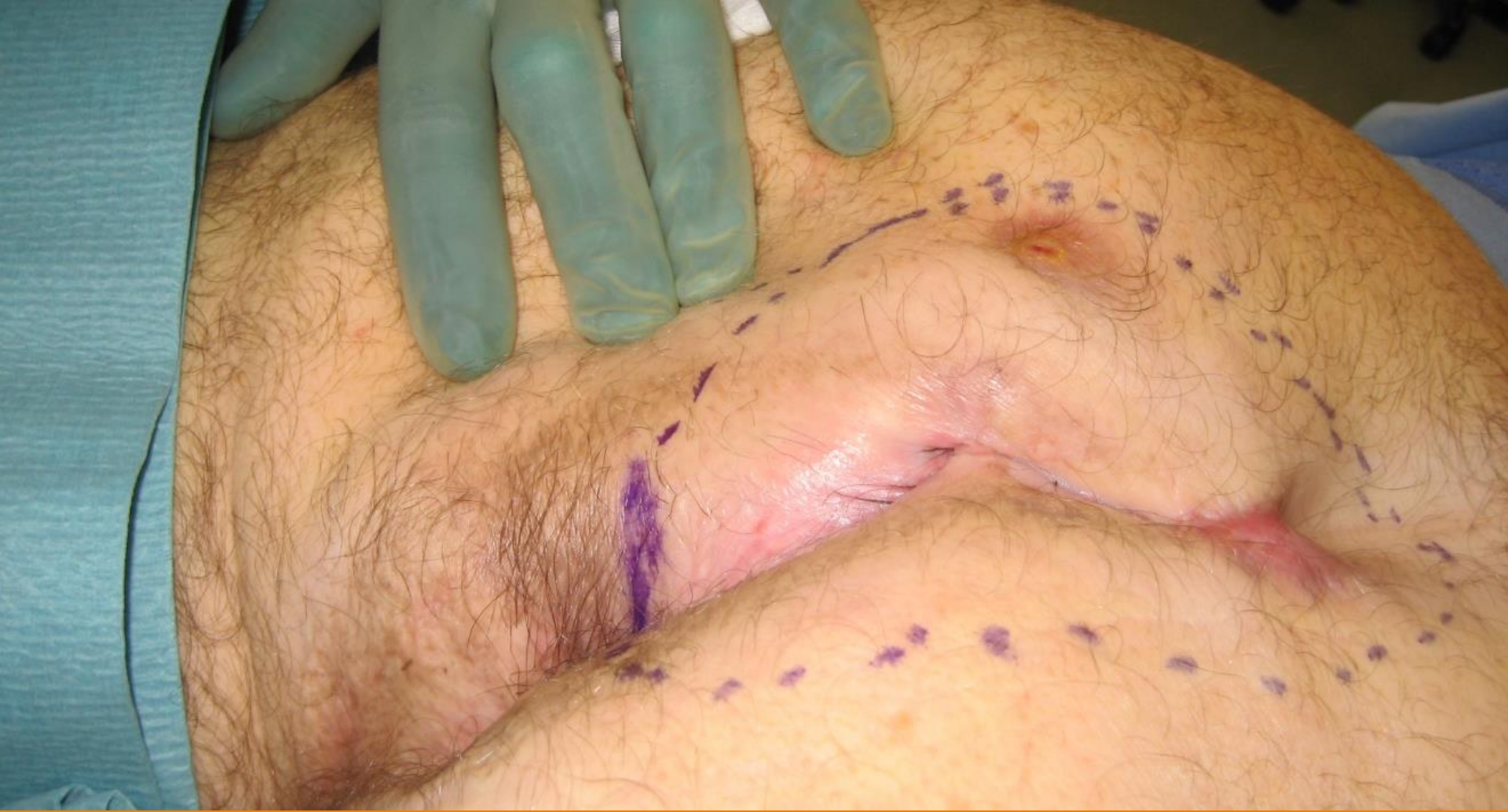**PD complicated by Hidradenitis suppurativa also treated with a double rotational flap (cranial base)**



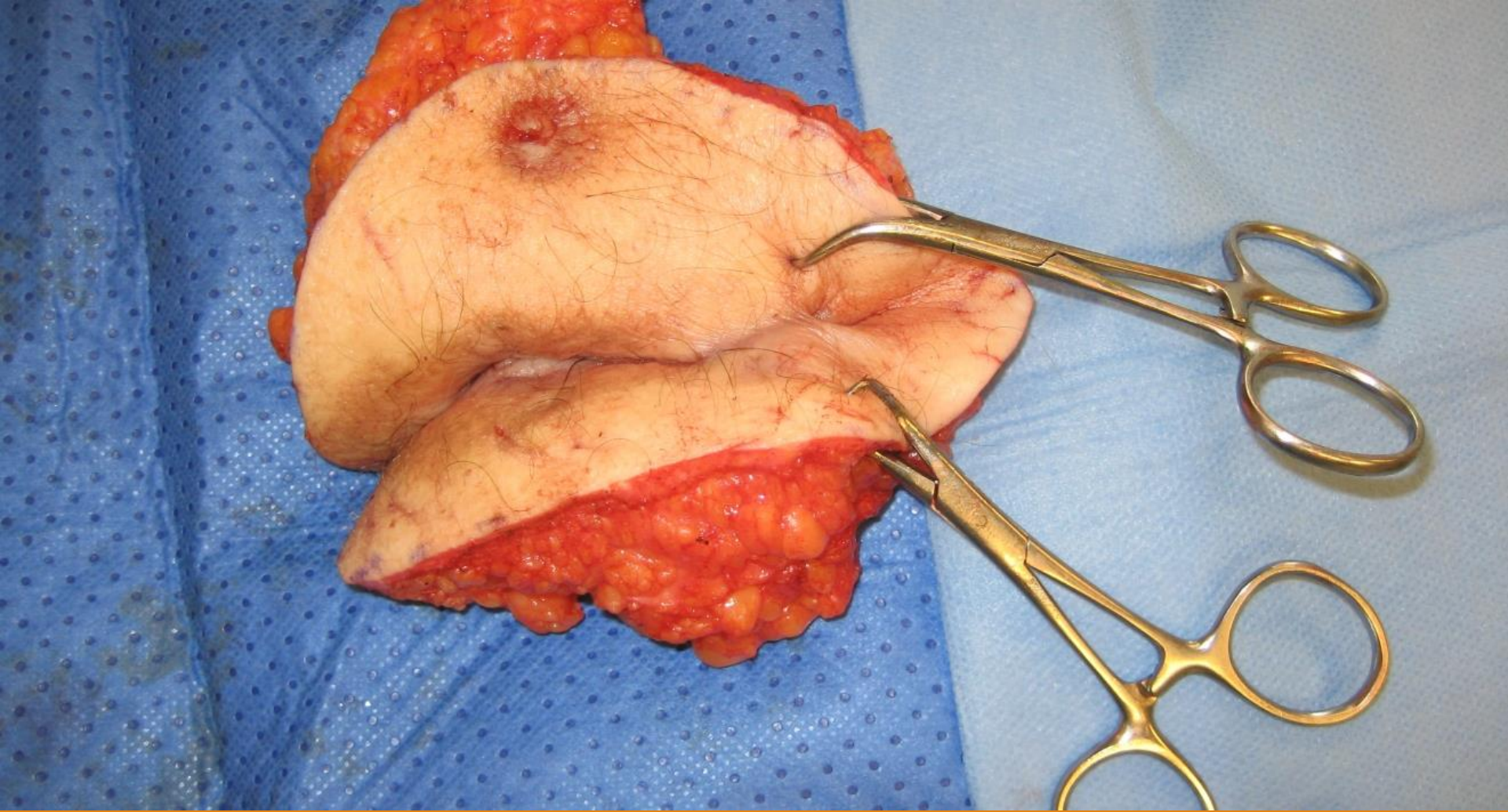


# RADICAL RESECTION

50 yr old patient who had received several PD surgeries but had continued recurrent disease.







**In these cases, radical resection is essential to achieve the best results**